

# Assessment of Alleged Retinal Laser Injuries

Martin A. Mainster, PhD, MD; Bruce E. Stuck, MS; Jeremiah Brown, Jr, MD, MS

**A**ccidental retinal laser injuries are easily diagnosed when there are known laser sources, typical macular injuries, and visual deficits consistent with retinal findings. Decisions are more difficult when retinal findings are subtle or absent, despite reported visual problems and somatic complaints. Inaccurate diagnosis of an ocular laser injury can precipitate a costly, lengthy sequence of medical and legal problems. Analysis of laser-tissue interactions and the characteristics of unambiguous retinal laser injuries provide 6 key questions to facilitate difficult diagnoses. Case reports demonstrate the usefulness of answering these questions before making diagnostic decisions. Retinal laser lesions that cause serious visual problems are readily apparent ophthalmoscopically and angiographically. Accidental, intentional, or clinical retinal laser lesions do not cause chronic eye, face, or head pains. Diagnosis of a retinal laser injury should be evidence based, not a matter of conjecture or speculation.

*Arch Ophthalmol.* 2004;122:1210-1217

It is well understood that accidental momentary exposure to an ordinary flashlight beam is annoying but safe. Accidental momentary exposure to a low-power laser pointer beam is also annoying but safe, yet it can evoke fear or outrage in some people.<sup>1-5</sup> Untoward responses to real or imagined laser exposures can have complex social and psychiatric explanations or more practical fiscal motivations. Ophthalmologists may be called on to determine whether a retinal laser injury is responsible for symptoms that reportedly follow an actual or perceived laser exposure incident. The proper analysis of those situations requires a clear understanding of the organic and psychophysical consequences of actual laser injuries, particularly when real but unrelated ophthalmic and systemic problems are present to confound the analysis.

## LASER EFFECTS

Exposure to UV radiation (200-400 nm), visible light (400-700 nm), and infrared radia-

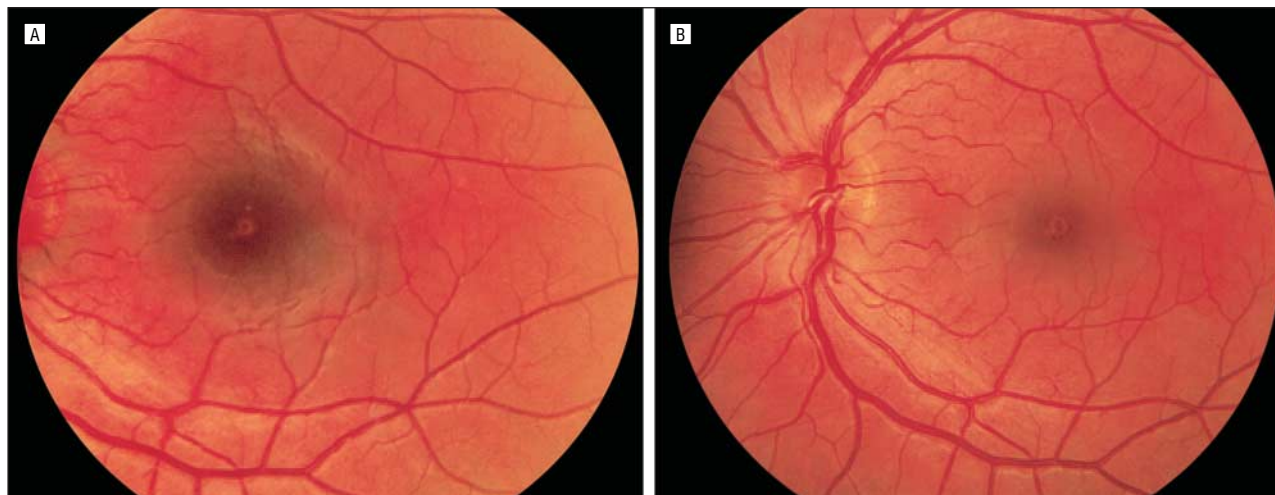
tion (700-10000 nm) can damage the eye.<sup>6-9</sup> Transmission and absorption of optical radiation by ocular media depend on the wavelength of the incident UV radiation, visible light, or infrared radiation.<sup>10</sup> Wavelength, pulse duration, spot size, and irradiance (power density, or laser power divided by area) determine the magnitude and lateral extent of temperature rises in exposed tissue produced by incident laser beams.<sup>11,12</sup>

*CME available at*  
[www.archophthalmol.com](http://www.archophthalmol.com)

Cornea and lens refraction produce retinal irradiances for laser beams that are up to  $10^5$  times greater than their corneal irradiances.<sup>13</sup> Laser radiation can damage the eye by photomechanical, photothermal, or photochemical mechanisms.<sup>8,9,14-16</sup> It is useful to differentiate between these mechanisms, but more than one effect may be involved in any particular injury.

Photomechanical injuries are caused by extremely high laser irradiances in very brief laser exposures ranging from hundreds of femtoseconds ( $10^{-15}$  seconds) to microseconds ( $10^{-6}$  seconds). Tissue is fragmented, perforated, or distorted immediately by a photomechanical injury.

*From the Department of Ophthalmology, University of Kansas Medical School, Kansas City (Dr Mainster); the United States Army Medical Research Detachment, Walter Reed Army Institute of Research, Brooks Air Force Base, Tex (Mr Stuck and Dr Brown); and Ophthalmology Associates, Nix Medical Center, San Antonio, Tex (Dr Brown). The authors have no relevant financial interest in this article.*



**Figure 1.** A mild accidental laser injury. A 21-year-old female technician accidentally looked into the exit aperture of a repetitively pulsed infrared Nd:YAG 1064-nm target designation laser. The technician reported seeing 2 or 3 yellowish flashes at the time of the laser exposure. Visual acuity in her left eye was 20/50 a few hours after the accident and 20/200 two days later; visual acuity returned to 20/15 two months after the injury. A, Four days after the accident, there is foveal edema, surrounding subretinal hemorrhage, and several small, hypopigmented retinal pigment epithelium lesions. B, One month after the accident, foveal edema and subretinal hemorrhage have resolved, and a small area of foveal retinal pigment epithelium degeneration has developed.

Clinical examples include photodisruption in Nd:YAG laser capsulotomy, photoablation in excimer laser keratorefractive surgery, and photovaporization in holmium:YAG laser thermokeratoplasty for hyperopia. Powerful Q-switched industrial or military lasers can cause severe retinal injuries when their radiation is absorbed in the retinal pigment epithelium (RPE) and underlying choroid.<sup>17-23</sup> In typical, accidental retinal injuries, rapid tissue expansion causes hemorrhage and prominent, permanent retinal scars.

Thermal laser injuries are produced by high laser irradiances in brief exposures ranging from microseconds to several seconds. Tissue protein coagulation often causes immediate or delayed blanching of the laser impact site and adjacent tissue. Clinical examples include argon laser panretinal photocoagulation and trabeculoplasty. Barely visible retinal photocoagulation lesions are associated with retinal temperature increases of 10°C.<sup>12,24-28</sup> Typical clinical photocoagulation lesions are associated with much higher retinal temperature increases (40°C-60°C).<sup>12,24,27,28</sup> Accidental cornea, iris, and crystalline lens injuries have been reported in clinical photocoagulation.<sup>29-34</sup> Accidental retinal laser lesions that produce substantial vision loss are apparent ophthalmoscopically or angiographically.<sup>17-23</sup>

Photochemical injuries occur when prolonged optical radiation exposure causes phototoxic chemical reactions in affected tissues<sup>8,16,35-37</sup> or when a previously administered exogenous photosensitizer is activated by an appropriate light source.<sup>38</sup> Clinical examples include solar and operating microscope maculopathy and verteporfin photodynamic therapy for age-related macular degeneration. Viewing intense light is very uncomfortable. Natural protective responses, such as squinting, pupillary constriction, and looking away from uncomfortably brilliant light sources, protect people from phototoxic retinal injuries, except in highly unusual, prolonged viewing circumstances, such as unprotected solar eclipse observation or welding arc viewing with a defective protective filter.<sup>6,9,39</sup>

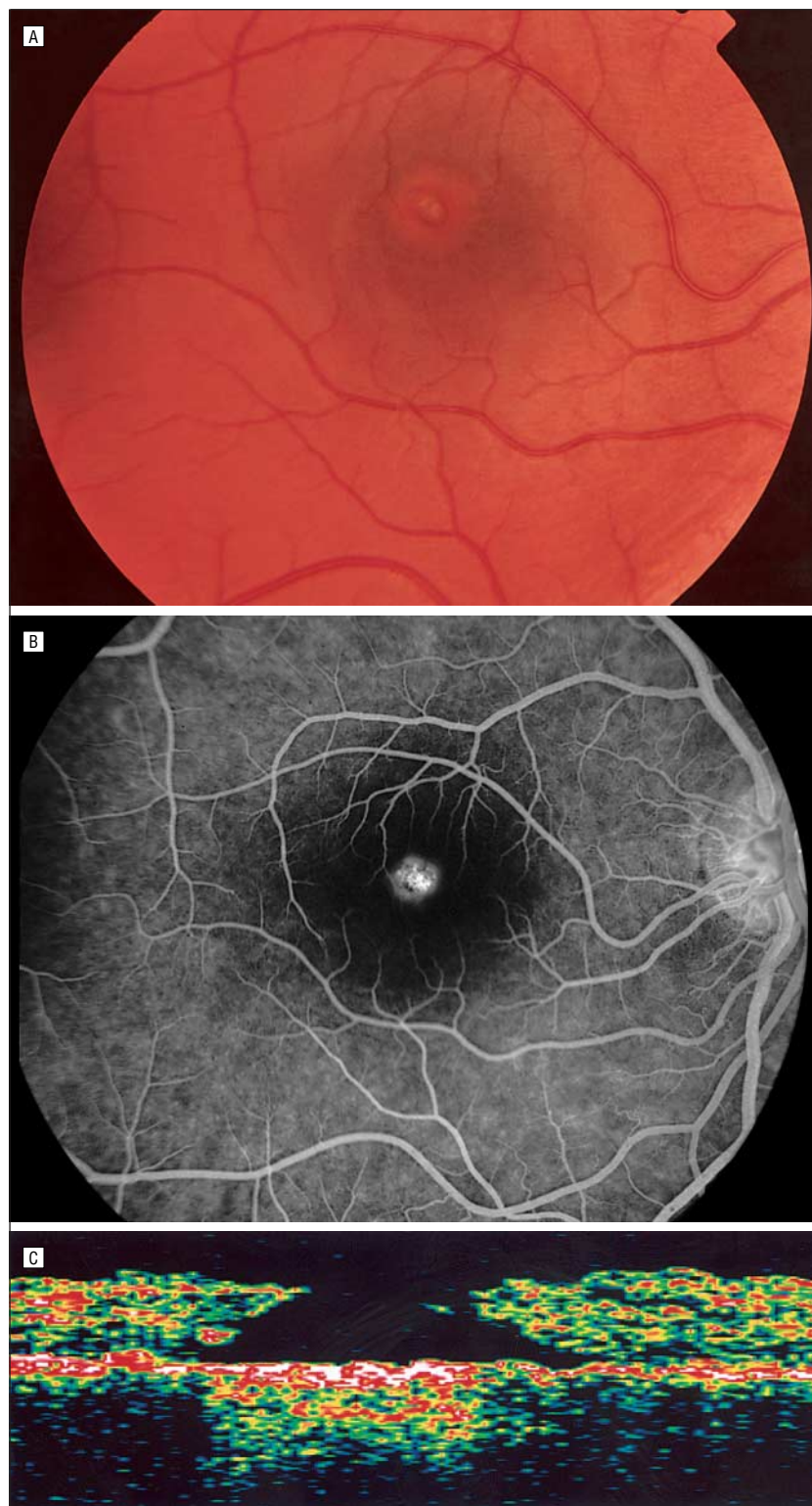
#### ACCIDENTS

It is estimated that fewer than 15 retinal injuries worldwide each year are caused by industrial and military lasers.<sup>17,22,40-44</sup> In most actual laser eye injuries, the laser source is known, typical chorioretinal damage occurs, there is an unambiguous temporal relationship between a laser incident and the onset of visual abnormalities that are well correlated with retinal findings, and retinal abnormalities remodel after the incident in a manner commensurate with their severity.

Laser eye injuries can be prevented by appropriate laser safety eyewear use. Unfortunately, laser safety glasses or goggles partially restrict vision, interfering with visually demanding laboratory, industrial, or military tasks. In addition, laser safety goggles can be uncomfortable and can fog in hot and humid environments. Most industrial accidents occur when a misfired laser beam enters an unshielded bystander's eye. Military injuries typically occur when a laser rangefinder or target designator beam is inadvertently or inappropriately viewed by an unprotected user or onlooker (**Figure 1** and **Figure 2**).<sup>46,47</sup> An ordinary laser pointer is safe, unless a user chooses to stare at its uncomfortable brilliant light for more than 10 seconds at close range, despite eye hazard labels warning users to avoid eye exposure.<sup>1-5</sup> Anterior segment eye injuries from lasers are rare because UV and infrared lasers that produce radiation with considerable corneal or crystalline lens absorption are typically used in well-controlled medical or industrial devices or environments. Most ocular laser accidents are caused by powerful Q-switched lasers that produce serious retinal injuries.<sup>19,20,22,42</sup>

#### SYMPTOMS AND FINDINGS

The severity of initial vision loss after a retinal laser injury depends on the distance of the laser impact site



**Figure 2.** A severe accidental laser injury. A 20-year-old male technician deliberately viewed the output of a laser rangefinder despite reading warning labels and undergoing laser safety training. He reported immediate vision loss in his right eye, with some improvement after 5 minutes. He sought medical assistance 18 hours after the injury, at which time visual acuity was 20/150 OD, where there was a macular and vitreous hemorrhage. The vitreous hemorrhage cleared, and his visual acuity returned to 20/70 during the next month. After the accident, visual acuity was 20/40 OD at 1 year and 20/30 OD at 2 years. A, Ten weeks after the injury, there is a full-thickness macular hole with surrounding retinal pigment epithelium depigmentation in the right eye. B, Fluorescein angiography documents a prominent foveal window defect due to retinal pigment epithelium atrophy. C, Optical coherence tomography documents a macular hole with increased reflectivity at its base. This increased reflectivity is a characteristic of laser-induced macular holes.<sup>45</sup> It is caused by choriocapillaris scarring, so the prognosis for visual improvement after macular surgery may be worse for laser-induced than idiopathic macular holes.<sup>45</sup>

from the center of the fovea, the extent of chorioretinal disruption, and the amount of chorioretinal bleeding. Victims of visually significant retinal laser injuries typically experience sudden, severe decreased vision in one or, less commonly, both eyes. They usually notice a bright flash of light even with invisible laser beams, followed by an immediate decrease in the vision of affected eyes. They occasionally hear a loud popping sound during a Q-switched chorioretinal laser injury. Vision may improve over several days to months. Visual prognosis is excellent if retinal findings are minor or do not involve the fovea. If the results of Amsler grid testing are abnormal, findings stabilize within a few months. These findings are consistent, stable, and well correlated with retinal findings in cooperative patients.

Momentary pain may occur at the time of ocular laser injury, but only rarely. This pain does not persist, just as it does not persist after clinical retinal photocoagulation. Noninjurious laser exposures and most laser injuries are painless, but rubbing an eye after a laser exposure can cause a painful transient corneal abrasion that individuals may attribute to laser exposure. Self-inflicted corneal abrasions are responsible for reported painful vision losses in children after laser pointer exposures.<sup>5</sup>

The most common initial clinical finding after an industrial or military Q-switched laser injury is prominent vitreous and/or chorioretinal hemorrhage from blood vessels ruptured by tissue distortion (Figure 2).<sup>17,20-22,40</sup> The number and size of blood vessels damaged at the laser impact site determine the extent of initial hemorrhage.<sup>23</sup> The location of the vessels and the structural integrity of adjacent tissue determine how effectively blood is tamponaded locally.<sup>23</sup> Large retinal areas can be rendered dysfunctional if blood spreads laterally into subhyaloid, subretinal, or sub-RPE spaces. Persistence of hemorrhage into subretinal spaces can cause photoreceptor deterioration.<sup>48</sup> Retinal holes and scarring can occur at the impact site (Figures 1 and 2).<sup>17,20-22,40</sup>

Fundus photography, fluorescein angiography, and optical co-



herence tomography are invaluable for determining whether retinal injury is present after a laser incident and, if so, whether visual complaints are consistent with documented retinal abnormalities. Acute photomechanical injuries typically produce a hypofluorescent spot at the laser impact site caused by vitreous or associated chorioretinal hemorrhage. As the hemorrhage resolves, a hyperfluorescent window defect may develop at the site owing to RPE damage (Figure 2), with hyperfluorescent staining of any fibrosis that develops after the injury. An RPE discontinuity or elevation is commonly seen on optical coherence tomograms immediately after and subsequent to photomechanical injuries (Figure 2). Acute photocoagulation lesions typically have a hypofluorescent center with a surrounding ring of faint hyperfluorescence. If a photocoagulation lesion is sufficiently small, there may be only a tiny hyperfluorescent spot at the injury site. Fluorescein leakage in the form of staining or pooling of dye at photocoagulation sites in late angiogram frames is common immediately after an injury. Acute photochemical lesions may have no angiographic abnormalities (as in mild solar maculopathy) or early hyperfluorescence with late leakage (as in operating microscope injuries).<sup>9</sup> Visually significant phototoxic lesions eventually produce angiographically apparent RPE abnormalities.

Retinal photography and fluorescein angiography should be performed as soon as possible after a suspected laser injury because there may be subvisible lesions if laser exposure variables are below thresholds for ophthalmoscopically apparent lesions. These tests are also important for dating chorioretinal findings and for determining whether concurrent systemic disease rather than laser injury could be their cause. Indocyanine green angiography may also be useful, particularly if it is performed using scanning laser ophthalmoscopy.

If there is no vitreous and/or chorioretinal hemorrhage to obscure the site, an acute laser injury is likely to produce a lesion with some fluorescein pooling or stain-

**Six Questions That Facilitate the Diagnosis of Alleged Retinal Laser Injuries**

1. Are there ocular abnormalities that could have been caused by a known laser-tissue interaction at the time of the reported incident?
2. If the answer to 1 is "yes," have those abnormalities been documented by a reliable technique, such as fundus photography, fluorescein angiography, or optical coherence tomography?
3. If the answers to 1 and 2 are "yes," do findings from ophthalmoscopy and retinal imaging evolve after the incident in a manner consistent with a laser injury?
4. If the answer to 1 is "yes" and substantial visual or somatic complaints are present, is there any scientific evidence that the objective ocular findings could cause the reported subjective complaints?
5. If the answer to 1 is "yes" and substantial visual complaints are present, is the location of Amsler grid or visual field defects stable and consistent with the location of the retinal abnormalities supposedly responsible for causing them?
6. If the laser source involved in the alleged injury is available or known, is it capable of producing the observed clinical findings under the reported exposure conditions?

ing, whereas an ordinary window defect on an angiogram performed within a week of a laser incident is more likely to be due to previous trauma, inflammation, or other natural processes. The possibility of pre-existing or concurrent eye or systemic problems makes it important to obtain a complete medical history and review of systems in cases of possible retinal laser injury, in addition to carefully reviewing copies of past medical records and retinal imaging if available.

Incidental angiographic findings should not be overinterpreted. For example, tiny RPE window defects occur routinely in angiograms with normal findings. In a small series of 50 consecutive fluorescein angiograms reviewed by one of us (M.A.M.), two thirds of the contralateral normal eyes of individuals with unilateral retinal problems had 1 or more tiny RPE window defects. The RPE is its own record of a lifetime of infection, trauma, inflammation, and other natural events. A few scattered RPE imperfections are neither surprising nor conclusively diagnostic of laser injury.

### DIAGNOSIS

The diagnosis of a laser injury can have considerable legal, financial, and medical consequences. It should be based on objective medical evidence rather than on unscientific speculation. Medicolegal problems arise when an injury is alleged but objective findings are absent, within normal limits, or explainable by unrelated medical problems. The ease

of diagnosing an actual laser injury is directly proportional to its severity. The answers to 6 facilitating questions are useful for diagnosing less severe or absent injuries after a real or imagined laser accident (**Table**). If the answer to question 1 is "no," then no visually significant laser injury has occurred. If the answers to all 6 questions are "yes," then a laser injury has almost certainly occurred.

Proper evaluation of a laser injury demands an exhaustive review of systems and medical history to rule out ocular or systemic causes for the ophthalmic and somatic complaints ascribed to a purported laser exposure. In suggestible or otherwise susceptible individuals, pain can represent an individual's somatization of a perceived although not organic ocular injury. Differentiating the psychiatric, financial, or other origins of nonorganic disorders is a challenging problem,<sup>49-60</sup> but perceived ocular injuries with no demonstrable tissue damage are not real laser injuries.

### CASE REPORTS

#### CASE 1

##### History

An 11-year-old girl stared at a red laser pointer beam held close to her right eye for more than 10 seconds to satisfy the curiosity of classmates on a school bus who wanted to know if her pupil would constrict.<sup>61</sup> She experienced no pain but developed decreased vision and a central scotoma immediately in her

right eye. Three weeks later, a retinal evaluation revealed central foveal pigment mottling with corresponding faint hyperfluorescence on fluorescein angiography. These findings became less prominent during the next 3 months as her scotoma resolved, and her uncorrected visual acuity returned to 20/25 OD, the same as in her unaffected left eye. She had no other ocular abnormalities in her right eye. In addition, this patient had no recent history of infection, inflammation, or mechanical trauma and no contributory past systemic or ocular history.

### Analysis

This 11-year-old girl probably experienced a 5-mW, 10-second, 50- $\mu$ m retinal spot diameter exposure that produced a 6° to 10° retinal temperature rise with a retinal irradiance of 160 W/cm<sup>2</sup> of diode 635-nm red light.<sup>5,62</sup> In comparison, clinical photocoagulation for diabetic retinopathy can be performed with a 200-mW, 0.2-second, 200- $\mu$ m retinal spot diameter exposure that produces a 40° to 60° retinal temperature rise with a retinal irradiance of 325 W/cm<sup>2</sup> of argon laser 514-nm green radiation.<sup>62</sup> Subvisible lesion transpupillary thermotherapy for occult choroidal neovascularization in age-related macular degeneration can be performed with an 800-mW, 60-second, 3-mm retinal spot diameter exposure that produces a 10° retinal temperature rise with a retinal irradiance of 7.5 W/cm<sup>2</sup> of diode laser 810-nm infrared radiation.<sup>62</sup>

Laser pointers sold in the United States are required to have an output power less than 5 mW.<sup>1,2,5,63</sup> Accidental momentary laser pointer exposure is safe because it is terminated in less than 0.25 second by normal aversion responses to uncomfortably brilliant light.<sup>1,2,5,64,65</sup> Prolonged viewing of a laser pointer beam for more than 10 seconds is potentially harmful,<sup>1</sup> which is the reason that these devices have warning labels. Retinal irradiance produced by a laser pointer held close to the eye is high because much of its power enters the eye and is concentrated into a small retinal spot. Conversely, heat conduction cools small retinal spots more effectively than large ones, so retinal tem-

perature rises for small-spot, 10-second laser pointer and large-spot, 60-second transpupillary thermotherapy exposures are comparable.<sup>11,24,62</sup> Thus, the most likely mechanism for the documented retinal damage caused by this laser pointer exposure is threshold transpupillary thermotherapy-type photocoagulation. In this case, the answers to all 6 diagnostic questions given in the Table are “yes,” and this episode is a case of laser injury.

### CASE 2

#### History

A prankster with a laser pointer momentarily exposed a middle-aged worker to the beam of an ordinary laser pointer from a distance of 9 m. The worker's visual acuity after the incident was 20/20 OU. In the 4 years after the episode, the worker developed headaches, progressive photophobia, and severe sharp and longer-lasting dull eye pains. His photophobia was disabling even when wearing sunglasses at ordinary indoor illumination levels. Visual field tests initially documented unilateral hemianopsia, although findings from magnetic resonance imaging were normal. Fluorescein angiography and eye examinations by numerous ophthalmologists immediately after and subsequent to the episode did not identify organic disease other than dry eye syndrome. The worker was then seen by a neuro-ophthalmologist, who diagnosed him as having photo-oculodinia syndrome<sup>66</sup> and attributed the origin of his pain, photophobia, and headaches to previous laser pointer exposure. The prankster's foolishness, the neuro-ophthalmologist's speculation that momentary laser pointer exposure can cause photo-oculodinia syndrome, and the worker's excellent employment record and reported absence of health or occupational problems before the incident probably influenced the defendant to settle this worker's damage claims out of court.

#### Analysis

Laser pointers are poor optical devices that contain a simple, inex-

pensive lens that collimates its diode laser's divergent, astigmatic beam. Assuming that a laser pointer beam has a full 5-mW output and a standard beam divergence of 1.5 milliradian, only 7% of the laser beam would enter a 4-mm-diameter pupil at a distance of 9 m. This exposure would produce a physiologic retinal temperature rise of only 0.4°C, which could not cause retinal injury. Furthermore, at a distance of 9 m from an artificial pupil, a laser pointer can be aimed through a 7-mm aperture at best only 25% of the time (B.E.S., D. J. Lund, BS, H. Zwick, PhD, D. A. Stamper, MS, P. R. Edsall, BS, J. W. Molchany, BS, unpublished data, 1999). Normal head movements and hand movements reduce any retinal exposure even more, so a laser pointer injury from a distance of 9 m is impossible without pupillary dilation and mechanically restraining and aligning both the laser pointer aperture and the observer's pupil for more than 10 seconds.

We could find only a single article<sup>66</sup> in the medical literature on photo-oculodinia syndrome, which is described as “a category of chronic eye pain triggered by even minor ocular trauma, when there is no evidence of ongoing tissue damage or inflammation.” The term was proposed as an alternative to the standard term “photophobia.”<sup>66</sup> Only 6 individuals with this condition were described in the article,<sup>66</sup> 3 of whom reported less discomfort after cervical sympathetic ganglion block. There is no scientific basis for the neuro-ophthalmologist's speculation that a complex ocular pain syndrome could be induced by brief, nondamaging light exposure. If that were the case, there would be millions of people with photo-oculodinia syndrome due to flash photography and laser eye surgery. In this case, the answers to diagnostic questions 1 and 6 in the Table are “no,” and this episode is not a case of laser injury.

### CASE 3

#### History

A young male soldier viewing the exit aperture of a laser rangefinder

that he was holding accidentally exposed his right eye to several powerful Q-switched, 1064-nm laser pulses.<sup>20</sup> He reported no pain but noticed an immediate decrease in vision in his right eye. Ophthalmic examination 24 hours later revealed vitreous hemorrhage overlying 2 retinal holes in his right fovea. Fluorescein angiography 5 days after the incident documented 3 prominent chorioretinal lesions with surrounding hyperfluorescence. Central macular scarring progressed in his right eye, and his visual acuity 18 months after the laser exposure was 20/400 OD.

### Analysis

Military Q-switched laser rangefinders and target designators are hazardous devices with radiation outputs that far exceed maximum permissible exposure levels.<sup>20,44,63</sup> Injuries to users and bystanders continue to occur infrequently despite careful precautions and safety training. In this case, the answers to all 6 diagnostic questions in the Table are "yes," and this episode is a case of laser injury.

### CASE 4

#### History

A 40-year-old male soldier observed 3 red light pulses emitted in 3 seconds by a tank approximately 3 km from his helicopter. He reported ocular discomfort for approximately an hour after the mission. These symptoms were relieved by acetaminophen use and did not recur. His visual acuity was 20/20 OU after the incident and when tested several times during the next 5 years. The soldier experienced metamorphopsia 7 years after the episode. He sought medical care 2 years later, concerned that he might be going blind from a laser exposure. When examined at that time, his uncorrected visual acuity was 20/20 OD and 20/50 OS, improvable to 20/20 OS, where his responses were slower. Findings from anterior segment examination were normal, but there were numerous yellow flecks in each macula, approximately 50 to 100  $\mu\text{m}$  in long-

est lateral extent. A foveal fleck was present in both eyes. Early fluorescein angiogram frames documented that the flecks had central hypofluorescence with a surrounding zone of hyperfluorescence. The hyperfluorescence faded in later images.

### Analysis

The soldier did not undergo a thorough retinal examination or retinal imaging studies until 9 years after the tank observation incident. At that time, ophthalmoscopy and fluorescein angiography documented pattern RPE dystrophy.<sup>67-69</sup> We know of no scientific evidence to suggest that this problem is caused or accelerated by light exposure. The tank that the soldier observed was probably equipped with a Q-switched ruby laser (694.3-nm, red) rangefinder. Q-switched retinal laser injuries typically cause immediate vision loss and a prominent, permanent chorioretinal scar. The soldier did not have vision loss after the incident or a chorioretinal scar consistent with laser injury. Furthermore, the type of ruby laser rangefinder known to be on the kind of tank he observed produces a retinal exposure far below international safety standards at a 3-km viewing distance.<sup>63,70</sup> In this case, the answers to questions 1 and 6 in the Table are "no," and this episode is not a case of laser injury.

### CASE 5

#### History

A middle-aged photographer had pain from a corneal abrasion after taking photographs of a ship. He surmised that there had been a laser device on the ship and that a laser injury had caused his discomfort. His visual acuity was 20/20 OU after the episode. A retina specialist found 3 tiny (10- to 20- $\mu\text{m}$ ) RPE window defects in one eye on a fluorescein angiogram and ascribed them to laser injury. Findings from optical coherence tomography were normal. Amsler grid test results were highly variable, and the locations of grid abnormalities and RPE defects were inconsistent.

During the next 5 years, the photographer developed chronic

headaches, photophobia, blurred vision, and nighttime driving and reading difficulties. He reported episodes of monocular diplopia. He also reported a constellation of terrible, intermittently disabling, periodic, and chronic eye and face pains. The initial retina specialist ascribed all these symptoms to laser injury. He also diagnosed a laser exposure in one of the photographer's companions present at the incident who reported similar symptoms but had completely normal findings on retinal examination and fluorescein angiograms.

A review of the photographer's voluminous medical history several years after the episode revealed dry eye syndrome, map-dot-fingerprint corneal dystrophy, temporomandibular joint syndrome, iritis, conjunctivitis, migratory arthritis, plantar fasciitis, chronic low back pain, epididymitis, and recurrent diarrhea. Most of the systemic problems predated the purported laser incident. New RPE defects developed after the incident. The photographer had not been diagnosed previously as having reactive arthritis (Reiter syndrome),<sup>71</sup> which can produce small RPE defects.<sup>72,73</sup> No evidence of laser injury was found in the years after the incident by 17 other ophthalmologists, including 5 neuro-ophthalmologists and 8 retina specialists. A trial was held 5 years after the incident in which the retina specialist who made the initial diagnosis steadfastly maintained that all the photographer's symptoms were due to retinal laser injury. A jury ruled against the photographer's claim for damages against the ship owner.

### Analysis

No laser was ever identified in this case despite a search of the ship. A costly, time-consuming chain of events was precipitated by the initial retina specialist's (1) failure to attach significance to an association between the photographer's symptoms and his complex past medical history, (2) quick diagnosis of a laser injury, (3) subsequent attribution of the photographer's growing list of pains and visual complaints to a laser injury, and (4) di-

agnosis of laser exposure in the photographer's associate based on symptoms in the absence of retinal or angiographic abnormalities. As noted previously herein, the few tiny RPE defects on which the initial diagnosis was based are common. Even if these defects were due to threshold laser effects, they could not have caused the photographer's reported problems or millions of patients would be afflicted with similar problems after routine retinal laser surgery. In this case, the answer to question 1 in the Table is "yes." Regarding question 2, there were angiographic findings but no optical coherence tomography abnormalities. The answers to questions 3, 4, and 5 are "no." Question 6 cannot be answered because there was no known laser source. The patient had real complaints, but they were caused by preexisting autoimmune problems rather than by laser injury.

#### COMMENT

Accidental laser injuries are rare. Complaints of laser injuries are more numerous. The ease of laser injury diagnosis is proportional to the severity of the injury. In ambiguous cases, subtle retinal findings should have excellent visual prognoses and clinical outcomes. Absence of a retinal lesion does not prove absence of laser exposure. Nonetheless, retinal laser lesions that cause serious visual problems are readily apparent ophthalmoscopically and angiographically. They remodel in the months that follow an injury. Actual retinal laser injuries do not cause chronic eye, face, or head pains. Thus, pains in the months that follow a real or imagined retinal laser injury are nonorganic or the result of regional or systemic problems unrelated to the laser incident. Fundus photography, fluorescein angiography, and optical coherence tomography should be performed as quickly as possible after a laser incident to document findings for analysis and comparison with subsequent tests.

The legal system has an uneasy relationship with "science" and "truth." Facts are welcomed by the attorneys of plaintiffs and defen-

dants only when they support their clients' biases and best interests. Medical "experts" are hired to advocate opinions that are often unrelated to evidenced-based medical practice. Juries struggle to separate reality from fiction. Attorneys may craft convincing cases for "victims" who claim severe pain and vision loss even when they have no physical evidence of injury. Patients with severe nonorganic problems of psychiatric origin or organic problems originating from problems unrelated to an injury may be dissuaded from solving these problems by hopes of financial gain.

A clinician's intransigence and misunderstanding of laser injury characteristics can be powerful allies of tort attorneys. When retinal laser injuries are alleged but uncertain because objective findings are minimal or absent, laser injury diagnosis should be deferred pending completion of a rigorous review and analysis of relevant laser devices and the purported victim's medical history, clinical course, ophthalmic examination findings, and retinal imaging study results. Such a review and analysis may take weeks or months to complete authoritatively. Hasty diagnoses should be avoided because they can create serious and lengthy medical, legal, and social issues. The 6 key diagnostic questions given in the Table provide a framework for evaluating potential laser injuries. The diagnosis of a laser injury should be evidence based, not a matter for speculation or conjecture. Retinal laser injuries do not cause chronic pain, and visually significant retinal laser injuries are apparent ophthalmoscopically and angiographically.

*Submitted for publication August 4, 2003; final revision received February 12, 2004; accepted March 25, 2004.*

*This study was supported in part by the Kansas Lions Sight Foundation Inc (Manhattan).*

*Correspondence: Martin A. Mainster, PhD, MD, Department of Ophthalmology, University of Kansas Medical School, 3901 Rainbow Blvd, Mail Stop 3009, Kansas City, KS 66160-7379 (mmainste@kumc.edu).*

#### REFERENCES

- Slaney DH, Dennis JE. Safety concerns about laser pointers. *J Laser Appl.* 1994;6:159-164.
- Mainster MA, Timberlake GT, Warren KA, Slaney DH. Pointers on laser pointers. *Ophthalmology.* 1997;104:1213-1214.
- Rockwell RJ Jr, Ertle WJ, Moss CE. Safety recommendation for laser pointers. *J Laser Appl.* 1998;10:174-180.
- Marshall J. The safety of laser pointers: myths and realities. *Br J Ophthalmol.* 1998;82:1335-1338.
- Mainster MA. Blinded by the light—not! *Arch Ophthalmol.* 1999;117:1547-1548.
- Slaney DH, Wolbarsht ML. *Safety With Lasers and Other Optical Sources: A Comprehensive Handbook.* New York, NY: Plenum Press; 1980.
- Mainster MA, Ham WT Jr, Delori FC. Potential retinal hazards: instrument and environmental light sources. *Ophthalmology.* 1983;90:927-932.
- Mellerio J. Light effects on the retina. In: Albert DM, Jakobiec FA, eds. *Principles and Practice of Ophthalmology.* Vol 1. Philadelphia, Pa: WB Saunders Co; 1994:1326-1345.
- Mainster MA, Turner PL. Photoc retinal injury and safety. In: Ryan SJ, Ogdan TE, Hinton DR, Schachat AP, eds. *Retina.* Vol 2. 3rd ed. St Louis, Mo: Mosby Inc; 2001:1797-1809.
- Boettner EA, Wolter JR. Transmission of the ocular media. *Invest Ophthalmol.* 1962;1:776-783.
- Mainster MA, White TJ, Allen RG. Spectral dependence of retinal damage produced by intense light sources. *J Opt Soc Am.* 1970;60:848-855.
- Mainster MA. Decreasing retinal photocoagulation damage: principles and techniques. *Semin Ophthalmol.* 1999;14:200-209.
- Slaney DH, Trokel SL. *Medical Lasers and Their Safe Use.* New York, NY: Springer-Verlag NY Inc; 1993.
- Mainster MA. Finding your way in the photoforest: laser effects for clinicians. *Ophthalmology.* 1984;91:886-888.
- Marshall J. Structural aspects of laser-induced damage and their functional implications. *Health Phys.* 1989;56:617-624.
- Glickman RD. Phototoxicity to the retina: mechanisms of damage. *Int J Toxicol.* 2002;21:473-490.
- Boldrey EE, Little HL, Flocks M, Vassiliadis A. Retinal injury due to industrial laser burns. *Ophthalmology.* 1981;88:101-107.
- Mainster MA, Slaney DH, Belcher CDI, Buzney SM. Laser photodisruptors: damage mechanisms, instrument design and safety. *Ophthalmology.* 1983;90:973-991.
- Wolfe JA. Laser retinal injury. *Mil Med.* 1985;150:177-185.
- Stuck BE, Zwick H, Molchany JW, Lund BJ, Gagliano DA. Accidental human laser retinal injuries from military laser systems. In: *SPIE Proceedings.* Vol 2674. Bellingham, Wash: SPIE—The International Society for Optical Engineering; 1996:7-20.
- Thach AB. Laser injuries of the eye. *Int Ophthalmol Clin.* 1999;39:13-27.
- Barkana Y, Belkin M. Laser eye injuries. *Surv Ophthalmol.* 2000;44:459-478.
- Mainster MA. Retinal laser accidents: mechanisms, management and rehabilitation. *J Laser Appl.* 2000;12:3-9.
- Mainster MA, White TJ, Tips JH, Wilson PW. Retinal-temperature increases produced by intense light sources. *J Opt Soc Am.* 1970;60:264-270.
- Cain CP, Welch AJ. Measured and predicted laser-induced temperature rises in the rabbit fundus. *Invest Ophthalmol.* 1974;13:60-70.



26. Priebe LA, Cain CP, Welch AJ. Temperature rise required for production of minimal lesions in the Macaca mulatta retina. *Am J Ophthalmol.* 1975; 79:405-413.
27. Birngruber R, Gabel VP, Hillenkamp F. Experimental studies of laser thermal retinal injury. *Health Phys.* 1983;44:519-531.
28. Roeder J, Hillenkamp F, Flotte T, Birngruber R. Microphotocoagulation: selective effects of repetitive short laser pulses. *Proc Natl Acad Sci U S A.* 1993;90:8643-8647.
29. Kanski JJ. Anterior segment complications of retinal photocoagulation. *Am J Ophthalmol.* 1975; 79:424-427.
30. Little HL. Complications of argon laser retinal photocoagulation: a five-year study. *Int Ophthalmol Clin.* 1976;16:145-159.
31. Irvine WD, Smiddy WE, Nicholson DH. Corneal and iris burns with the laser indirect ophthalmoscope. *Am J Ophthalmol.* 1990;110:311-313.
32. Woon WH, fytche TJ, Hamilton AM, Marshall J. Iris clipping of a diode laser beam when performing retinal photocoagulation. *Br J Ophthalmol.* 1991;75:386-390.
33. Bloom SM, Mahl CF, Schiller SB. Lenticular burns following argon panretinal photocoagulation. *Br J Ophthalmol.* 1992;76:630-631.
34. Pogrebniak AE, Bolling JP, Stewart MW. Argon laser-induced cataract in an infant with retinopathy of prematurity. *Am J Ophthalmol.* 1994;117:261-262.
35. Noell WK, Walker VS, Kang BS, Berman S. Retinal damage by light in rats. *Invest Ophthalmol.* 1966;5:450-473.
36. Ham WT Jr, Mueller HA, Sliney DH. Retinal sensitivity to damage from short wavelength light. *Nature.* 1976;260:153-155.
37. Kremers JJ, van Norren D. Two classes of photochemical damage of the retina. *Lasers Light Ophthalmol.* 1988;2:41-52.
38. Schmidt-Erfurth U, Hasan T. Mechanisms of action of photodynamic therapy with verteporfin for the treatment of age-related macular degeneration. *Surv Ophthalmol.* 2000;45:195-214.
39. Stamper DA, Lund DJ, Molchany JW, Stuck BE. Human pupil and eyelid response to intense laser light: implications for protection. *Percept Mot Skills.* 2002;95:775-782.
40. Gabel VP, Birngruber R, Lorenz B, Lang GK. Clinical observations of six cases of laser injury to the eye. *Health Phys.* 1989;56:705-710.
41. Rockwell RJ Jr. Laser accidents: reviewing thirty years of incidents: what are the concerns—old and new? *J Laser Appl.* 1994;6:203-211.
42. Thach AB, Lopez PF, Snady-McCoy LC, Golub BM, Frambach DA. Accidental Nd:YAG laser injuries to the macula. *Am J Ophthalmol.* 1995;119:767-773.
43. Ness JW, Hoxie SW. Database structure for the Laser Accident and Incident Registry (LAIR). In: *SPIE Proceedings.* Vol 2974. Bellingham, Wash: SPIE—The International Society for Optical Engineering; 1997:2-7.
44. Stuck BE, Zwick H, Lund BJ, Scales DK, Gagliano DA. Accidental human retinal injuries by laser exposure: implications to laser safety. *Int Laser Safety Conference Proc.* 1997;3:576-585.
45. Allen RD, Brown J Jr, Zwick H, Schuschereba ST, Lund DJ, Stuck BE. Laser-induced macular holes demonstrate impaired choroidal perfusion. *Retina.* 2004;24:92-97.
46. Mellerio J, Marshall J, Tengroth B, Anderberg B, Wolbarsht M. Battlefield laser weapons: an assessment of systems, hazards, injuries and ophthalmic resources required for treatment. *Lasers Light Ophthalmol.* 1991;4:41-67.
47. Tengroth B, Anderberg B. Blinding laser weapons. *Lasers Light Ophthalmol.* 1991;4:35-39.
48. Hochman MA, Seery CM, Zarbin MA. Pathophysiology and management of subretinal hemorrhage. *Surv Ophthalmol.* 1997;42:195-213.
49. Drews RC. Organic versus functional ocular problems. *Int Ophthalmol Clin.* 1967;7:665-696.
50. Kramer KK, La Piana FG, Appleton B. Ocular malingering and hysteria: diagnosis and management. *Surv Ophthalmol.* 1979;24:89-96.
51. Keltner JL, May WN, Johnson CA, Post RB. The California syndrome: functional visual complaints with potential economic impact. *Ophthalmology.* 1985;92:427-435.
52. Keltner JL. The California syndrome: a threat to all. *Arch Ophthalmol.* 1988;106:1053-1054.
53. Fahle M, Mohn G. Assessment of visual function in suspected ocular malingering. *Br J Ophthalmol.* 1989;73:651-654.
54. Bose S, Kupersmith MJ. Neuro-ophthalmologic presentations of functional visual disorders. *Neurol Clin.* 1995;13:321-339.
55. Barsky AJ, Borus JF. Somatization and medicalization in the era of managed care. *JAMA.* 1995; 274:1931-1934.
56. Martin TJ. Threshold perimetry of each eye with both eyes open in patients with monocular functional (nonorganic) and organic vision loss. *Am J Ophthalmol.* 1998;125:857-864.
57. Barsky AJ, Borus JF. Functional somatic syndromes. *Ann Intern Med.* 1999;130:910-921.
58. Mojon DS, Schlapfer TE. Nonorganic disorders in ophthalmology: overview of diagnosis and therapy. *Klin Monatsbl Augenheilkd.* 2001;218:298-304.
59. Graf MH, Roesen J. Ocular malingering: a surprising visual acuity test. *Arch Ophthalmol.* 2002; 120:756-760.
60. Scott JA, Egan RA. Prevalence of organic neuro-ophthalmologic disease in patients with functional visual loss. *Am J Ophthalmol.* 2003;135: 670-675.
61. Sell CH, Bryan JS. Maculopathy from handheld diode laser pointer. *Arch Ophthalmol.* 1999;117: 1557-1558.
62. Mainster MA, Reichel E. Transpupillary thermotherapy for age-related macular degeneration: long-pulse photocoagulation, apoptosis, and heat shock proteins. *Ophthalmic Surg Lasers.* 2000;31:359-373.
63. *American National Standard for the Safe Use of Lasers, ANSI Z136.1-2000.* Washington, DC: American National Standards Institute; 2000.
64. Mensah E, Vafidis G, Marshall J. Laser pointers: the facts, media hype, and hysteria. *Lancet.* 1998; 351:1291.
65. Robertson DM, Lim TH, Salomao DR, Link TP, Rowe RL, McLaren JW. Laser pointers and the human eye: a clinicopathologic study. *Arch Ophthalmol.* 2000;118:1686-1691.
66. Fine PG, Digre KB. A controlled trial of regional sympatholysis in the treatment of photo-oculodystonia syndrome. *J Neuroophthalmol.* 1995; 15:90-94.
67. Marmor MF, McNamara JA. Pattern dystrophy of the retinal pigment epithelium and geographic atrophy of the macula. *Am J Ophthalmol.* 1996; 122:382-392.
68. Zhang K, Garibaldi DC, Li Y, Green WR, Zack DJ. Butterfly-shaped pattern dystrophy: a genetic, clinical, and histopathological report. *Arch Ophthalmol.* 2002;120:485-490.
69. Quillen DA, Blodi BA. *Clinical Retina.* Chicago, Ill: American Medical Association Press; 2002.
70. International Commission on Non-Ionizing Radiation Protection. Guidelines on limits of exposure to broad-band incoherent optical radiation (0.38 to 3 μm). *Health Phys.* 1997;73:539-554.
71. Lee DA, Barker SM, Su WP, Allen GL, Liesegang TJ, Ilstrup DM. The clinical diagnosis of Reiter's syndrome: ophthalmic and nonophthalmic aspects. *Ophthalmology.* 1986;93:350-356.
72. Conway RM, Graham SL, Lassere M. Incomplete Reiter's syndrome with focal involvement of the posterior segment. *Aust N Z J Ophthalmol.* 1995; 23:63-66.
73. Needham AD, Harding SP, Carey P. Bilateral multifocal choroiditis in Reiter syndrome. *Arch Ophthalmol.* 1997;115:684-685.